

Disorder of Sexual Development with Sex Chromosome Mosaicism 46 XY and 47 XXY

Sampath Kumar Govindaraj, Lakshmidhevi Muralidhar, Shreedhar Venkatesh, Rajiv Kumar Saxena

ABSTRACT

Incidence of abnormalities of sex chromosome is reported to be 1 in 448 new born babies. The association between clinical phenotype and sex chromosome abnormality is highly variable. A 34-year-old unmarried female patient reported to out patient department with complaints of primary amenorrhea and occasional pain in the lower abdomen. On examination, her height was 160 cm and body mass index (BMI) was 27 kg/m². Breast development was Tanner stage 4, pubic hair was tanners stage 1 and no axillary hair was noted. Ultrasonography showed a hypoechoic structure in the place of uterus measuring around 1.7 × 1.1 × 1.0 cm and hypoechoic structures were also noted in relation to iliac vessels suggestive of gonads. Karyotyping showed 46 XY and 47 XXY mosaicism. Bilateral gonadectomy was done and histopathology showed testicular atrophy with Leydig cell hyperplasia. This case is reported in view of the interesting clinical presentation of this rare mosaicism.

Keywords: Disorder of sexual development, Gonadectomy, Karyotype, Mosaicism.

How to cite this article: Govindaraj SK, Muralidhar L, Venkatesh S, Saxena RK. Disorder of Sexual Development with Sex Chromosome Mosaicism 46 XY and 47 XXY. *Int J Infertility Fetal Med* 2013;4(1):34-37.

Source of support: Nil

Conflict of interest: None

INTRODUCTION

Incidence of abnormalities in sex chromosome is 1 in 448 new born babies.¹ The association between clinical phenotype and sex chromosome abnormality is highly variable.² Disorder of sexual development is the new terminology used for any abnormality of sex chromosome and abnormal genital development. Aim of presentation of this case is an opportunity to revisit the new classification of disorders of sexual development (DSD) and the rarity of the DSD with mosaicism.

CASE REPORT

A 34-year-old unmarried female patient reported to out patient department with complaints of primary amenorrhea and occasional pain in the lower abdomen (inguinal region). There was no history of primary amenorrhea or unexplained neonatal death in the family.

On examination, her height was 160 cm and BMI was 27 kg/m². Breast development was Tanner stage 4, pubic hair was tanners stage 1. She did not have any axillary hair. Abdominal examination did not reveal any mass or hernia in the inguinal region. On local examination, labia majora and minora were well developed and there was a blind vagina of 2.5 cm length. On rectal examination, a small nodular structure was present in the region of the uterus of around 1-2 cm in length. Mild tenderness was present in both the inguinal region.

Patients hormonal profile revealed raised serum testosterone of 899 ng/dl. Serum FSH and LH were normal. Ultrasonography showed a hypoechoic structure in place of uterus, measuring around 1.7 × 1.1 × 1.0 cm (Fig. 1). Hypoechoic structures were also noted in relation to iliac vessels suggestive of gonads (Fig. 2) even though no follicles were noted. Karyotype showed 46 XY and 47 XXY mosaicism (Fig. 3).

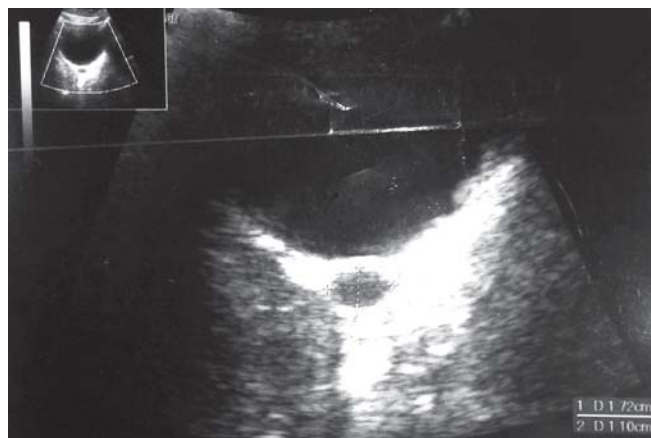


Fig. 1: USS rudimentary uterus

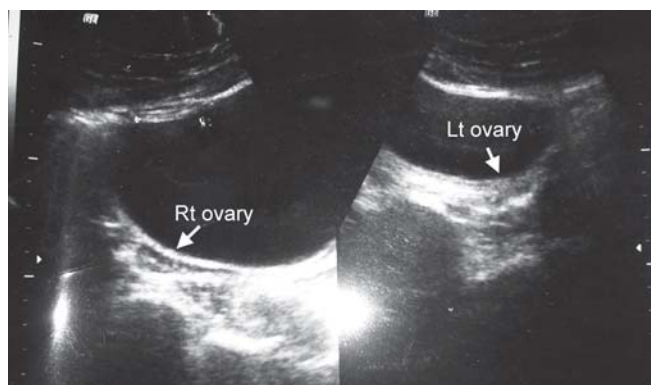


Fig. 2: USS ovaries

Date of Received: 04-03-13

Date of Acceptance: 14-03-13

Date of Publication: January 2013

Patient was counselled about the absence of her menstrual and reproductive potential. She was also counselled that she would need serial dilatation of vagina to achieve her coital function. In view of the presence of Y chromosome, she was counselled regarding the risk of malignancy and the necessity for removal of her gonads.

As the patient could not afford laparoscopic surgery, she underwent exploratory laparotomy and gonadectomy, under general anesthesia. A small knob-like structure around $2 \times 1 \times 1$ cm was present in the region of uterus (Fig. 4), tubes and ovaries were absent. Retroperitoneal space was explored along the iliac vessels on both the sides, but rudimentary gonad could not be located. Decision was taken for exploration of inguinal canal, gonad of around $2 \times 3 \times 2$ cm on the left side and $4 \times 2 \times 1$ cm on the right side were located near the external inguinal ring. Bilateral gonadectomy was done and the gonads were sent for histopathology (Figs 5 and 6).

Microscopy section showed sheets and lobules of Leydig cells interspersed with occasional seminiferous tubules, which appeared atrophic and lined by sertoli cells. No atypia was seen. Final impression was testicular atrophy with Leydig cell hyperplasia (Fig. 7).

Patient was discharged on seventh postoperative day, with counseling for hormone replacement therapy, and serial dilatation of the vagina for coital function and the need for long-term follow-up.

DISCUSSION

In more than 80% of primary amenorrhea, the cause is either Mullerian agenesis, gonadal dysgenesis or hypogonadotropic hypogonadism.³ Karyotyping is advised in young individuals with hypergonadotropic amenorrhea and those with congenital absence of uterus. This is to identify the Y chromosome or its fragment(s) as the gonads or gonadal ridges of these patients are at high risk for malignant transformation. As malignant transformation in the gonadal ridge could occur at any age, the streak gonads should be removed as soon as the diagnosis is made, except for complete androgen insensitivity syndrome where gonadectomy can be delayed until the patient has completed pubertal development.

Risk of malignancy is about 20 to 30% in 46 XY gonadal dysgenesis and 15 to 20% in case of 46 XY and 45 X mixed gonadal dysgenesis. Malignancy in a case of mixed gonadal dysgenesis is often seen early in 1st or 2nd decade of life.

This condition needs multidisciplinary approach for assessment and management, and consequently will require long-term monitoring and support.

Management of a case of DSDs with androgen insensitivity syndrome should address the following issues:⁴

- Making a correct diagnosis.
- Communicating the diagnosis to the patient and parent with expert psychiatric counseling.

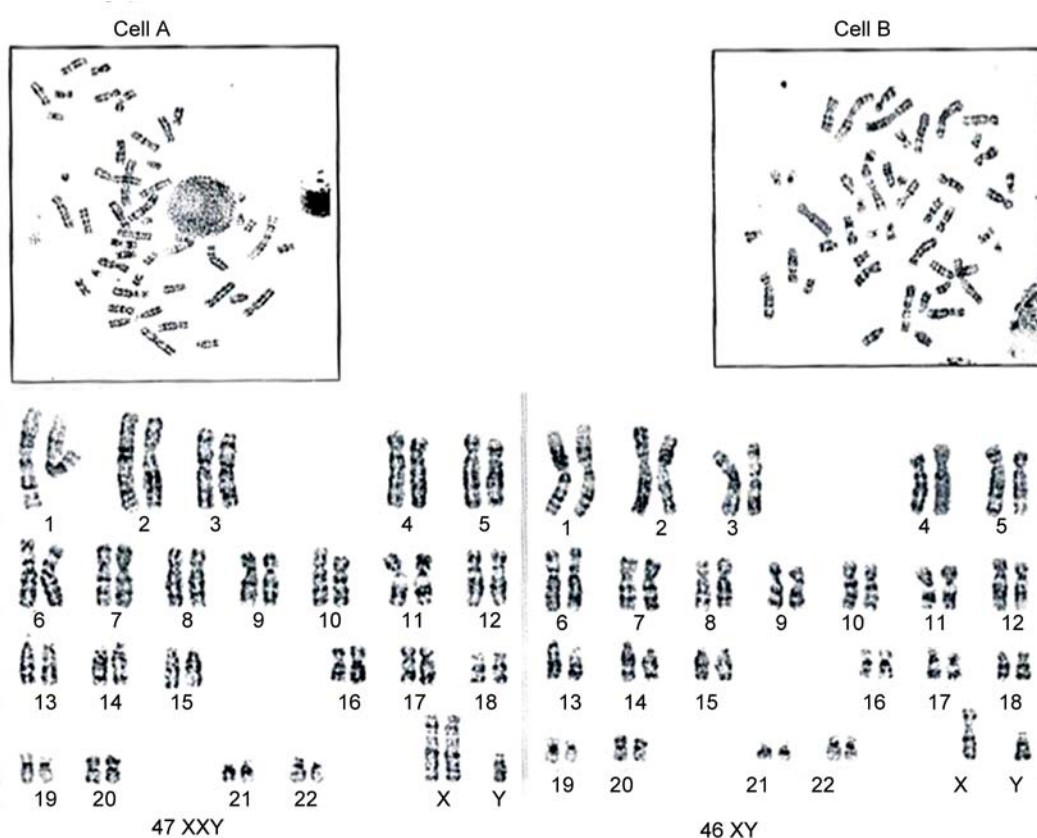


Fig. 3: Karyotype

- c. Need of early gonadectomy because of the risk of malignancy. About 5% of dysgerminomas are associated with 46 XY, 45 X/46 XY and other sex chromosome mosaicism.⁵
- d. Need of hormone replacement therapy following gonadectomy, for the induction of puberty and maintenance of bone mineral density.
- e. Treatment of vaginal hypoplasia in XY females.

A new taxonomy based on the umbrella term, 'DSD' has been proposed to describe atypical sexual differentiation. Many DSDs are associated with ambiguous genitalia, and present at birth, however, a few may present with delayed puberty or primary amenorrhea. The terms, such as intersex, hermaphrodite, pseudohermaphrodite have been perceived as pejorative and stigmatizing, leading to a feeling of shame in affected patients and their families. The DSDs are classified into:

- 1. Sex chromosome DSDs (which includes conditions like 45 X Turner and variants, 47 XXY Klinefelter and its variants, 45 X/46 XY mixed gonadal dysgenesis (MGD)

and chromosomal ovotesticular DSD '46 XX/46 XY chimeric type or mosaic type').

- 2. 46 XY DSDs (include disorders of testicular development or disorders in androgen synthesis/action) and
- 3. 46, XX DSDs (include disorders of ovarian development or fetal androgen excess). It is recognized that some conditions do not fit exactly into one specific diagnostic category or may be placed in more than one category. The DSD nomenclature has recently divided 'ovotesticular DSD' (formerly true hermaphroditism) into 46 XY ovotesticular DSD, 46 XX ovotesticular DSD, and chromosomal ovotesticular DSD (46 XX/46 XY chimerism or 45 X/46 XY' mosaic type). Gonul Ocal has put forth a scholarly discussion on this new classification, including the reasons for this new classification.⁵

Management of patients with DSD and related conditions focus on four major issues as follows:

- 1. Aetiological diagnosis
- 2. Assignment of gender

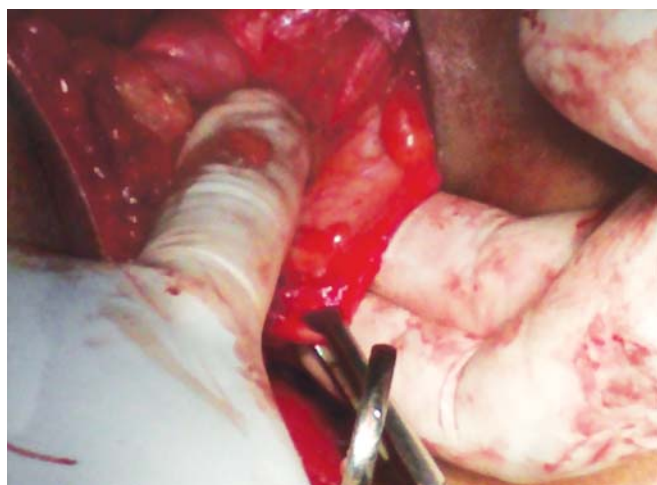


Fig. 4: Rudimentary uterus

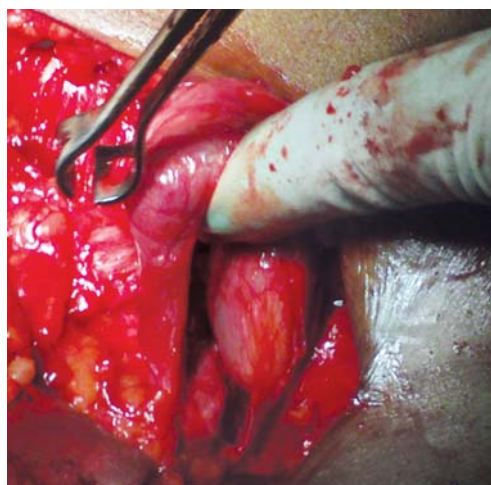

Fig. 6: Right gonad

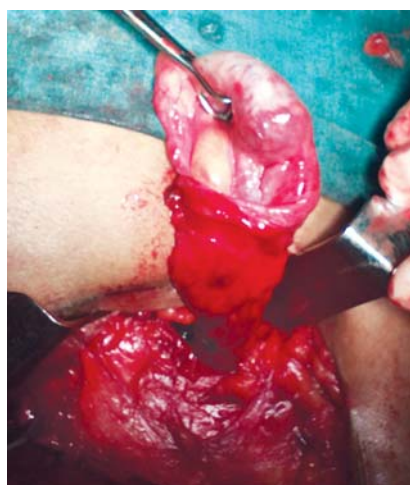


Fig. 5: Left gonad at external inguinal ring

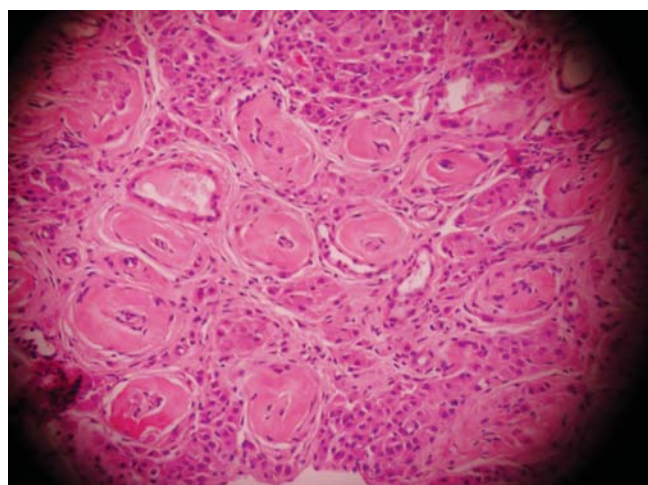


Fig. 7: Atrophic seminiferous tubules

3. Indication for and timing of genital surgery
4. The disclosure of medical information to the patient and his/her parents.

Disorder of sexual development with 46 XY and 47 XXY karyotype is one of the rare forms of sex chromosome abnormality. The psychological and social implications of gender assignment require a multi-disciplinary approach. Risk of malignancy, fertility and psychosexual functions and needs must be addressed on an individual basis.¹

REFERENCES

1. Jyothy A, Kumar KSD, Swarna M, Sekhar MR, Umadevi B, Reddy PP. Cytogenetic investigations in 1843 referral cases of disordered sexual development from Andhra Pradesh, India. *IJHG* 2002;2(1):55-59.
2. Shrivastava S, Nisha B, Unnikrishnan AG, Praveen VP, Muralidharan MV, Nair V, et al. An interesting case of 46XY/45X gonadal dysgenesis (mixed gonadal dysgenesis) *IJCCI* 2011;2(5):8-10.
3. Tanmahasamut P, Rattanachaiyanont M, Dangrat C, Indhavivadhana S, Angsuwattana S, Techatraisak K. Causes of primary amenorrhea: A report of 295 cases in Thailand. *J Obstet Gynaecol Res* 2012 Jan;38(1):297-301. DOI: 10.1111/j.1447-0756.2011.01677.x. Epub 2011 Nov 9.
4. Bhat BPR, Navada HM. XY females: Two cases with different gonads presenting as primary amenorrhoea. *WJOES* 2012;4(1):23-25.
5. Ocal G. Current concepts in disorders of sexual development. *J Clin Res Ped Endo* 2011;3(3):105-14. DOI: 10.4274/jcrpe.v3i3.22

ABOUT THE AUTHORS

Sampath Kumar Govindaraj (Corresponding Author)

Professor, Department of Obstetrics and Gynecology, Vydehi Institute of Medical Sciences and Research Centre, Bangaluru, Karnataka India, e-mail: drsankumar.58@gmail.com

Lakshmidivi Muralidhar

Assistant Professor, Department of Obstetrics and Gynecology, Vydehi Institute of Medical Sciences and Research Centre, Bangaluru Karnataka, India

Shreedhar Venkatesh

Professor and Head, Department of Obstetrics and Gynecology Vydehi Institute of Medical Sciences and Research Centre, Bangaluru Karnataka, India

Rajiv Kumar Saxena

Professor, Department of Obstetrics and Gynecology, Vydehi Institute of Medical Sciences and Research Centre, Bangaluru, Karnataka, India